

# Association between Total Knee Arthroplasty and Subtalar Joint Changes: A Cadaver Study

Dominick J. Casciato, B.A.<sup>1\*</sup>, Natalie A. Builes, B.A.<sup>2</sup>, Luis A. Rodriguez Anaya, DPM<sup>1</sup>, Bibi N. Singh, DPM<sup>1</sup>

<sup>1</sup>Barry University School of Podiatric Medicine, Department of Basic Medical Sciences, Miami Shores, Florida

<sup>2</sup>Nova Southeastern University: College of Pharmacy

\*Corresponding Author: Dominick J. Casciato; Dominick.casciato@mymail.barry.edu

**Background:** Total knee arthroplasty (TKA) has become the procedure of choice for those suffering from debilitating degenerative joint disease of the knee; however, new research suggests that functional changes in the rearfoot occur following the procedure to compensate for gait changes. This pilot study investigates subtalar joint (STJ) changes in cadavers with TKAs.

**Methods:** Four embalmed cadavers with a unilateral TKA were disarticulated at the STJ and the calcaneal articular facets were imaged. The length, width, and area of these facets ipsilateral to the joint replacement were measured using image analysis software and compared to the contralateral side.

**Results:** All cadavers exhibited evidence of anatomical changes at the STJ. Moreover, a transition to an anatomically unstable STJ was observed.

**Conclusions:** This study suggests that biomechanical compensation at the STJ may result in anatomical changes in the joint in which form of the joint follows function. Though this pathology may have developed prior to such arthroplasty, the unilateral nature of the facet changes emphasizes the need to further investigate and address gait abnormalities before and after joint replacement to optimize biomechanics in the arthritic knee.

**Keywords:** Arthroplasty; Biomechanics; Cadaver Study; Joint Replacement; Orthopedics; Orthotics; Osteoarthritis

## INTRODUCTION

The evolution of the total knee arthroplasty (TKA) has provided patients with joint pain and decreased mobility due to osteoarthritis (OA) the opportunity to improve function and comfort.<sup>1-3</sup> This procedure, however, has been shown to cause an accelerated and nonrandom deterioration of other joints in the lower extremity.<sup>4-6</sup> Current research concerning patients with OA, both before and after a unilateral TKA, supports a model of progressive joint deterioration secondary to limb length discrepancies and biomechanical compensatory mechanisms.<sup>7,8</sup> Furthermore, kinematic and gait analyses present evidence for such compensatory mechanisms to occur in the rearfoot.<sup>9-12</sup> In accordance with Wolff's Law, which states that a bone will adapt to loads it is placed under, there should be altered anatomy observed in the rearfoot following compensation for debilitating OA and the subsequent TKA. It follows that if changes in bony architecture secondary to abnormal gait biomechanics in the severely arthritic knee occur, such

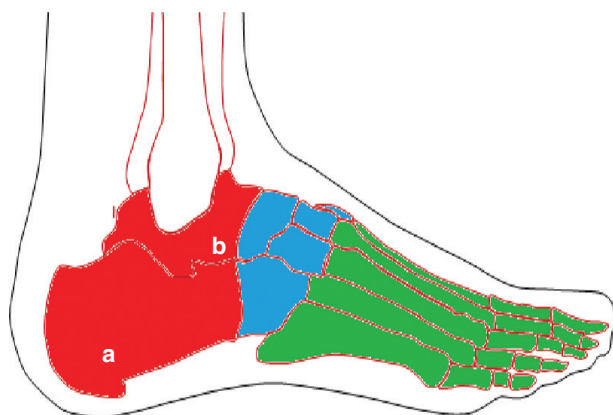
remodeling would be seen at the subtalar joint (STJ): the articulation responsible for most of the currently proposed compensatory mechanisms.<sup>9,13-15</sup>

There is a paucity of data that connects biomechanical compensation to anatomical changes of the foot ipsilateral to knees with a total joint replacement. This pilot study aims to describe anatomical changes present at the STJ in limbs ipsilateral and contralateral to the TKA. Though such physiologic changes may occur prior to implantation of the artificial joint, the purpose of this project is to investigate if osseous changes occur at the STJ in joints with and without a TKA, not when such changes occur. These changes emphasize the need to further investigate and address gait abnormalities before and after joint arthroplasty.

## Anatomy

The foot consists of three separate regions: the forefoot, midfoot, and rearfoot as illustrated in Figure 1. The rearfoot comprises the talus and calcaneus which articulate with the leg superiorly and the midfoot anteriorly. The talus

and calcaneus articulation forms the STJ, a synovial joint.<sup>16</sup> One, two, or three osseous facets provide the surface for STJ articulation.<sup>17</sup> Each facet is named based on location: anterior, medial, and posterior. These convex facets sit on the superior surface of the calcaneus, and articulate with complementary, concave facets on the inferior surface of the talus. Three basic types of calcanei shown in Fig. (2) have been described based on these facets.<sup>16–18</sup> Furthermore, the configuration of facets has been implicated in the pathomechanics of gait abnormalities with the two-facet design in the anterior STJ proposed as the most stable.<sup>18,19</sup>



**Figure 1.** Anatomic relationship of the (a) calcaneus and (b) talus in the (green) forefoot, (blue) midfoot, and (red) rearfoot.

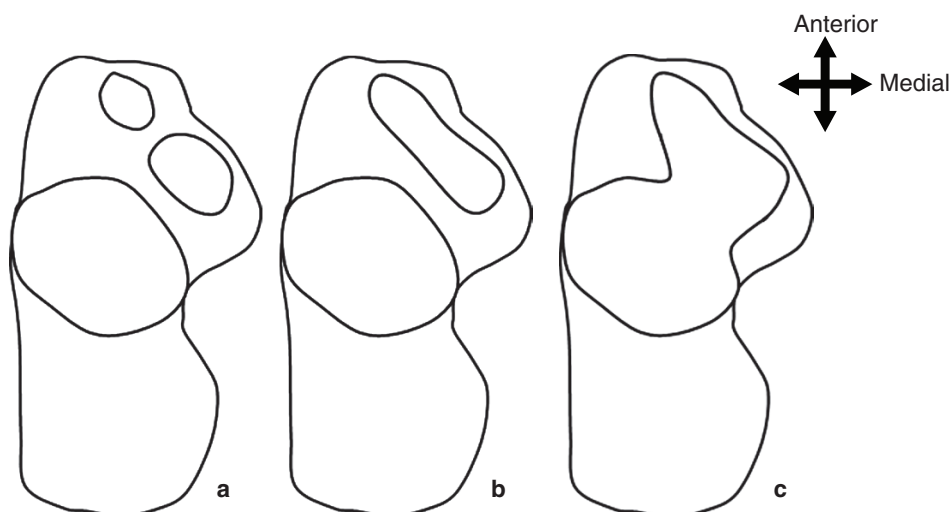
[AQ9]

## Biomechanics

Historically, the STJ is known to move about an axis that is located 42 degrees off the transverse plane and 16 degrees medial to the sagittal plane between the first and second toes.<sup>20–22</sup> The STJ maintains motion in all three planes, or has a triplanar motion.<sup>23,24</sup> Such motion depends on whether the joint is in an open kinetic chain (OKC) or closed kinetic chain (CKC). In CKC, as seen in the stance phase of gait when the limb bears weight, the talus becomes mobile around a stable forefoot. Triplanar motion in CKC occurs through pronation (calcaneal eversion, tibial internal rotation, knee flexion, talar plantarflexion, and adduction) and supination (calcaneal inversion, tibial external rotation, knee extension, talar dorsiflexion and abduction). Pronation and supination serve as compensation mechanisms for functional or postural deformities of the lower extremity affecting gait.<sup>24</sup> When these compensatory mechanisms become pathologic, a variety of foot orthoses can be employed to control several aspects of rearfoot motion. From short-leg walking casts to custom-made foot orthoses, these conservative therapies have been shown to relieve pain, reduce rearfoot pronation, and improve function in patients with orthopedic conditions involving the rearfoot.<sup>25</sup>

## METHODS

This study was granted exempt status by the Barry University Institutional Review Board under protocol



**Figure 2.** Types of calcanei. (a) Type A calcaneus with three distinct facets. (b) Type B calcaneus with confluent anterior and medial facets and distinct posterior facet. (c) Type C calcaneus with one confluent facet.

number 170601. The four embalmed cadavers used in this study were obtained from the Anatomical Board of the State of Florida. The cadavers selected exhibited a unilateral TKA and no signs of surgery to either limb from the hip distally. Each foot was disarticulated at the STJ, then imaged using a Canon Power Shot SX40 HS perpendicular to the superior surface of the calcaneus as illustrated in Fig. (3a). The anterior, medial, and posterior calcaneal facets were outlined by one medical student and one pharmacy student with no knowledge of which bone belonged to which leg. The outlines were then averaged to create the geometric shape of each facet and analyzed using ImageJ, an image processing program.<sup>26</sup> The length, width, and area of these facets were then measured as shown in Fig. (3b).

## RESULTS

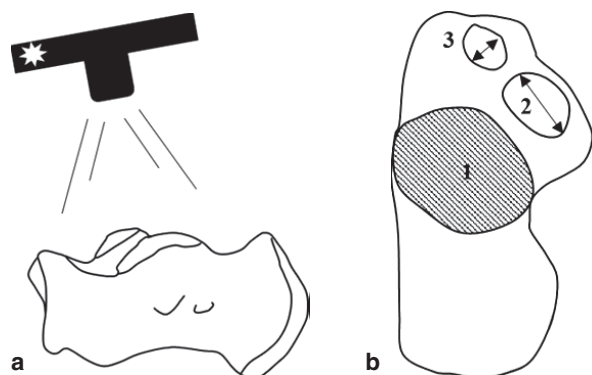
Of the four pairs of calcanei included in the study, three pairs were of the Type A variation (Fig. 4: Pairs 1–3) and one pair was of the Type B variation (Fig. 4: Pair 4).

### Posterior Facet

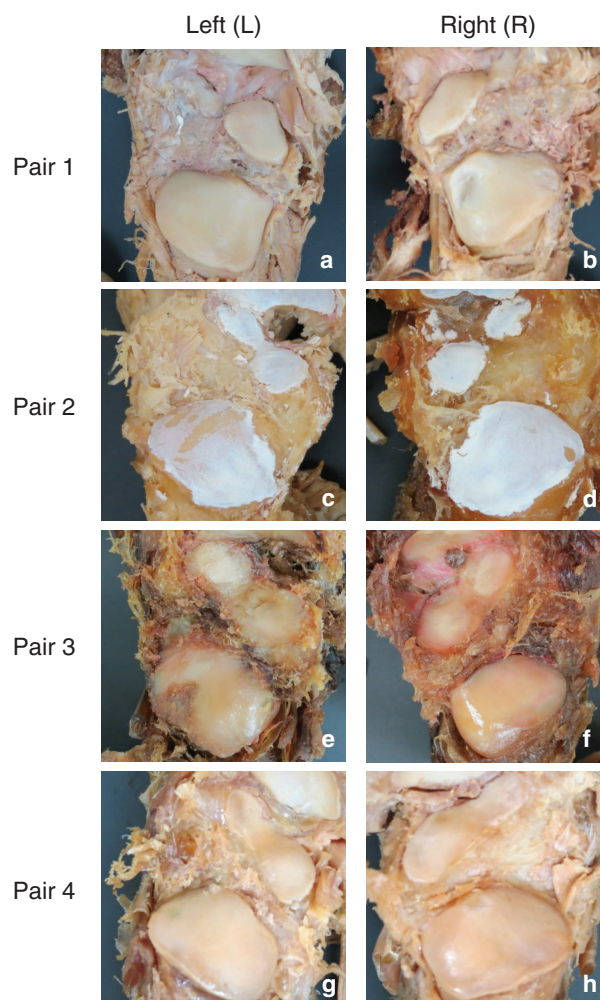
Three out of the four pairs of calcanei exhibited posterior facets in terms of area, length, and width in the TKA limb than the same facets in the opposite non-TKA limb as reported in Table 1.

### Medial Facet

All Type A medial facets on the TKA leg exhibited a larger area than the medial facets belonging to the non-TKA leg. Two out of three medial facet pairs on the TKA leg reported in Table 2 were longer and with a smaller width than the non-TKA leg.



**Figure 3.** Data collection, (a) Calcaneus imaged perpendicular to each articular facet from the dorsal surface. (b) Dorsal view of selected area (1), major (2), and minor (3) axes of left calcaneus.



**Figure 4.** Imaged calcaneal facets: type A Calcaneus-Pair 1. (a) Non TKA; (b) TKA side, pair 2; (c) TKA; (d) Non TKA side, Pair 3; (e) Non TKA; (f) TKA side. Type B Calcanei – Pair 4 (g) Non TKA; (h) TKA side.

**Table 1.** Posterior facet data.

Pair	Area (mm <sup>2</sup> )	Length (mm)	Width (mm)
1L	611.2	32.9	23.6
1R*	569.7	32.2	22.5
2L*	772.5	34.9	28.2
2R	647.6	33.1	24.9
3L	663.0	33.8	25.0
3R*	456.5	29.3	19.9
4L	606.2	32.3	23.9
4R*	559.1	30.8	23.1

\*Denotes side ipsilateral to TKA.

**Table 2.** Medial facet data.

Pair	Area (mm <sup>2</sup> )	Length (mm)	Width (mm)
<b>1L</b>	191.8	18.9	12.9
<b>1R*</b>	195.5	23.4	10.6
<b>2L*</b>	161.1	15.5	13.2
<b>2R</b>	157.4	17.0	11.8
<b>3L</b>	123.7	16.4	9.6
<b>3R*</b>	153.2	15.6	12.5

\*Denotes side ipsilateral to TKA.

**Table 3.** Anterior facet data.

Pair	Area (mm <sup>2</sup> )	Length (mm)	Width (mm)
<b>1L</b>	57.9	12.1	6.1
<b>1R*</b>	59.4	13.5	5.6
<b>2L*</b>	85.5	14.0	7.8
<b>2R</b>	73.3	12.6	7.4
<b>3L</b>	78.6	13.2	7.6
<b>3R*</b>	67.0	11.8	7.2
<b>4L<sup>†</sup></b>	240.1	30.9	9.9
<b>4R*<sup>†</sup></b>	289.8	34.2	10.8

\*Denotes side ipsilateral to TKA.

<sup>†</sup>Denotes combined anterior and medial facets.

### Anterior Facet

Two out of three anterior facet pairs on the TKA side exhibited a larger facet area compared to the contralateral non-TKA leg. Two out of three anterior facet pairs ipsilateral to the TKA limb were longer and less wide than the contralateral non-TKA leg as indicated in Table 3.

### Combined Medial and Anterior Facet

The Type B calcaneal facet pair exhibited a larger facet area on the TKA leg than the non-TKA leg. The length and width were also greater in the TKA leg than the non-TKA leg as shown in Table 3.

### DISCUSSION

The advent of TKA has allowed those suffering from debilitating OA to ambulate with less pain.<sup>3</sup> This pathology and subsequent joint replacing procedure, however, has been shown to alter hindfoot mechanics.<sup>27-29</sup> The purpose of our study is to identify anatomical changes associated with these altered mechanics.

In our study, all of the Type A calcanei ipsilateral to the TKA began to show confluence between the anterior and medial facets – described as a ‘transitional two-facet’ variation.<sup>18</sup> This change can most easily be seen in Fig. (4c). The transition from a three-facet to a two-facet configuration suggests a structural compensation toward a more biomechanically unstable variation.<sup>18,30</sup> This compensation is due to the medial facet limiting medial rotation of the talus during heel strike in the three-facet configuration.<sup>30</sup> In contrast, the two-facet variation does not limit medial rotation of the talus during heel strike. This uninhibited movement creates laxity at the plantar calcaneonavicular ligament that connects the calcaneus to the navicular. This ligamentous laxity is responsible for a biomechanically unstable foot.<sup>31</sup>

In all pairs of feet, the STJ ipsilateral to the TKA exhibited a larger medial or confluent anterior/medial facet. A similar trend was also observed in two out of three anterior facets ipsilateral to the TKA. These increases in area support the original hypothesis that TKA leads to structural changes in the STJ.

The increase in width and length of medial and anterior facets respectively of Type A calcanei ipsilateral to the TKA may contribute to the transition toward a more unstable two-facet variation. An increase in both the length and width of the Type B calcanei shows continued structural changes even in the more unstable variation.

As this study demonstrates, structural evidence of functional changes at the STJ exists in a limb necessitating unilateral TKA. A possible explanation of the results reported in this study includes greater CKC loading as well as pronation and supination ipsilateral to the pathologic limb during gait. More specifically, an increase in talar plantarflexion and adduction at the STJ would cause the anterior and medial facets, and ultimately the plantar calcaneonavicular ligament, to bear a greater load than normal. Following Wolff’s Law, these facets would adapt and remodel themselves to resist the load increase, predisposing the joint to conditions favorable to arthritis. Remodeling of these facets, even if arthritic, secondary to compensatory gait would explain the structural changes observed in this study.

Our results further support the current use of orthotics to control STJ and rearfoot motion following OA.<sup>32-35</sup> Such orthoses and braces would aim to control this abnormal motion in patients who are experiencing pain during



ambulation. Through the management of the arthritic knee and subsequent corrective surgery with functional orthoses or bracing, compensatory structural or arthritic changes may be alleviated, potentially limiting articular facet remodeling in the STJ. A future direction of research may include studying patients who undergo TKA, and compare long-term foot and ankle pain scores between groups who use orthoses or bracing following the TKA to those who do not use such devices.

There were a few limitations with this study that can be addressed with future research. Since only four cadavers were available for use in this study, the sample size was small; however, preliminary results support the initial hypothesis. Another limitation encountered was the inability to measure an accurate limb length. Moreover, embalming made it difficult to accurately measure hindfoot varus or valgus, important values that could be addressed *in vivo*.

## CONCLUSION

In conclusion, STJ changes were observed in limbs that have undergone a TKA. These changes reflect altered biomechanics existing both before and after the joint replacement. This form follows function model and supports the use of bracing or orthotic devices to functionally control STJ and rearfoot motion in patients necessitating a unilateral TKA. These findings emphasize the importance of a preoperative gait evaluation to preemptively address postoperative compensatory gait abnormalities and illustrate the need for further research regarding biomechanical changes before and after joint arthroplasty.

## Conflict of interest and funding:

None of the authors report any conflicts of interest. The authors have not received any funding or benefits from industry or elsewhere to conduct this study.

## REFERENCES

1. Liddle AD, Pegg EC, Pandit H. Knee replacement for osteoarthritis. *Maturitas* 2013; 75(2): 131–6. doi: 10.1016/j.maturitas.2013.03.005
2. Loughhead JM, Malhan K, Mitchell SY, Pinder IM, McCaskie AW, Deehan DJ, et al. Outcome following knee arthroplasty beyond 15 years. *Knee* 2008; 15(2): 85–90. doi: 10.1016/j.knee.2007.11.003
3. Carr AJ, Robertsson O, Graves S, Price AJ, Arden NK, Judge A, et al. Knee replacement. *Lancet* 2012; 379: 1331–40. doi: 10.1016/S0140-6736(11)60752-6
4. Alice BM, Stéphane A, Yoshisama SJ, Pierre H, Domizio S, Hermes M, et al. Evolution of knee kinematics three months after total knee replacement. *Gait Posture* 2015; 41(2): 624–9. doi: 10.1016/j.gaitpost.2015.01.010
5. Shakoor N, Block JA, Shott S, Case JP. Nonrandom evolution of end-stage osteoarthritis of the lower limbs. *Arthritis Rheum* 2002; 46(12): 3185–9. doi: 10.1002/art.10649
6. Lee JH, Jeong BO. Radiologic changes of ankle joint after total knee arthroplasty. *Foot Ankle Int* 2012; 33(12): 1087–92. doi: 10.3113/FAI.2012.1087
7. Noll DR. Leg length discrepancy and osteoarthritic knee pain in the elderly: An observational study. *J Am Osteopath Assoc* 2013; 113(9): 67–8. doi: 10.7556/jaoa.2013.033
8. Vaidya S V, Patel MR, Panghate AN, Rathod PA. Total knee arthroplasty: Limb length discrepancy and functional outcome. *Indian J Orthop* 2010; 44(3): 300–7. doi: 10.4103/0019-5413.65159
9. Levinger P, Menz HB, Morrow AD, Bartlett JR, Feller JA, Fotoohabadi MR, et al. Dynamic foot function changes following total knee replacement surgery. *Knee* 2012; 19(6): 880–5. doi: 10.1016/j.knee.2012.05.002
10. Levinger P, Menz HB, Morrow AD, Feller JA, Bartlett JR, Bergman NR. Lower limb biomechanics in individuals with knee osteoarthritis before and after total knee arthroplasty surgery. *J Arthroplasty* 2013; 28(6): 994–9. doi: 10.1016/j.arth.2012.10.018
11. Ulrich SD, Bhavé A, Marker DR, Seyler TM, Mont MA. Focused rehabilitation treatment of poorly functioning total knee arthroplasties. *Clin Orthop Relat Res* 2007; 464: 138–45. doi: 10.1097/BLO.0b013e3181560d99
12. Cho WS, Cho HS, Byun SE. Changes in hindfoot alignment after total knee arthroplasty in knee osteoarthritic patients with varus deformity. *Knee Surg Sports Traumatol Arthrosc* 2017; 25(11): 3596–3604.
13. Levinger P, Menz HB, Morrow AD, Bartlett JR, Feller JA, Bergman NR. Relationship between foot function and medial knee joint loading in people with medial compartment knee osteoarthritis. *J Foot Ankle Res* 2013; 6(1): 33. doi: 10.1186/1757-1146-6-33
14. Levinger P, Menz HB, Morrow AD, Feller JA, Bartlett JR, Bergman NR. Foot kinematics in people with medial compartment knee osteoarthritis. *Rheumatol (United Kingdom)* 2012; 51(12): 2191–8. doi: 10.1093/rheumatology/kes222
15. Levinger P, Menz HB, Fotoohabadi MR, Feller JA, Bartlett JR, Bergman NR. Foot posture in people with medial compartment knee osteoarthritis. *J Foot Ankle Res* 2010; 3(1): 29. doi: 10.1186/1757-1146-3-29
16. Kelikian AS, Sarrafian SK. Sarrafian's anatomy of the foot and ankle: Descriptive, topographic, functional. 3rd ed. New York: Lippincott Williams & Wilkins; 2011.
17. Bunning PS, Barnett CH. A comparison of adult and foetal talocalcaneal articulations. *J Anat* 1965; 99(1): 71–6.
18. Bruckner J. Variations in the human subtalar joint. *J Orthop Sports Phys Ther* 1987; 8(10): 489–94. doi: 10.2519/jospt.1987.8.10.489

- 19.** Katoh Y, Chao EY, Laughman RK, Schneider E, Morrey BF. Biomechanical analysis of foot function during gait and clinical applications. *Clin Orthop Relat Res* 1983; 177: 23–33. Available from: <http://www.ncbi.nlm.nih.gov/pubmed/6861400> [cited 19 December 2017].
- 20.** Kirby KA. Subtalar joint axis location and rotational equilibrium theory of foot function. *J Am Podiatr Med Assoc* 2001; 91(9): 465–87. doi: 10.7547/87507315-91-9-465
- 21.** Rockar PA. The subtalar joint: Anatomy and joint motion. *J Orthop Sports Phys Ther* 1995; 21(6): 361–72. doi: 10.2519/jospt.1995.21.6.361
- 22.** Manter JT. Movements of the subtalar and transverse talar joints. *Anat Rec* 1941; 80(4): 397–409. doi: 10.1002/ar.1090800402
- 23.** Root ML, Orien WP, Weed JH. Normal abnormal function foot. Los Angeles: Clinical Biomechanics Corp; 1977.
- 24.** Donatelli RA. Abnormal biomechanics of the foot and ankle. *J Orthop Sports Phys Ther* 1987; 9(1): 11–16. doi: 10.2519/jospt.1987.9.1.11
- 25.** Sobel E, Levitz SJ, Caselli MA. Orthoses in the treatment of rearfoot problems. *J Am Podiatr Med Assoc* 1999; 89: 220–33. doi: 10.7547/87507315-89-5-220
- 26.** Rasband WS. ImageJ. 2016. Available from: <https://imagej.nih.gov/ij/> [cited 19 December 2017].
- 27.** Takenaka T, Ikoma K, Ohashi S, Arai Y, Hara Y, Ueshima K, et al. Hindfoot alignment at one year after total knee arthroplasty. *Knee Surg Sport Traumatol Arthrosc* 2016; 24(8): 2442–6. doi: 10.1007/s00167-015-3916-x
- 28.** Hara Y, Ikoma K, Arai Y, Ohashi S, Maki M, Kubo T. Alteration of hindfoot alignment after total knee arthroplasty using a novel hindfoot alignment view. *J Arthroplasty* 2015; 30(1): 126–9. doi: 10.1016/j.arth.2014.07.026
- 29.** Güven M, Kocadal O, Akman B, Şayli UAF. Pedobarographic analysis in total knee arthroplasty. *J Knee Surg* 2017; 30(9): 951–9.
- 30.** Drayer-Verhagen F. Arthritis of the subtalar joint associated with sustentaculum tali facet configuration. *J Anat* 1993; 183(Pt 3): 631–4. doi: 10.16965/ijar.2014.525
- 31.** Harrington I. Biomechanics of musculoskeletal injury. Baltimore, MD: Williams & Wilkins; 1982.
- 32.** Kerrigan DC, Lelas JL, Goggins J, Merriman GJ, Kaplan RJ, Felson DT. Effectiveness of a lateral-wedge insole on knee varus torque in patients with knee osteoarthritis. *Arch Phys Med Rehabil* 2002; 83(7): 889–93. doi: 10.1053/apmr.2002.33225
- 33.** Sasaki T, Yasuda K. Clinical evaluation of the treatment of osteoarthritic knees using a newly designed wedged insole. *Clin Orthop Relat Res* 1987; (221): 181–7. Available from: <http://www.ncbi.nlm.nih.gov/pubmed/3608298> [cited 19 December 2017].
- 34.** Yasuda K, Sasaki T. The mechanics of treatment of the osteoarthritic knee with a wedged insole. *Clin Orthop Relat Res* 1987; (215): 162–72. doi: 10.1097/00003086-198702000-00024
- 35.** Keating EM, Faris PM, Ritter MA, Kane J. Use of lateral heel and sole wedges in the treatment of medial osteoarthritis of the knee. *Orthop Rev* 1993; 22(8): 921–4. Available from: <http://www.ncbi.nlm.nih.gov/pubmed/8265230> [cited 19 December 2017].